Orthopaedic examination of the dog 2. Pelvic limb

Gareth Arthurs

Gareth Arthurs graduated from Cambridge in 1996. He spent four years in mixed practice and three years in general small animal practice. Since 2003, he has worked purely as a referral small animal orthopaedic surgeon. He is currently a lecturer in small animal surgery at the Royal Veterinary College, where he is also head of surgery. He holds the RCVS diploma in small animal surgery (orthopaedics).

An orthopaedic examination should help to determine whether the cause of any lameness, weakness, lethargy, intolerance, ataxia or incoordination is due to an orthopaedic condition, to localise the orthopaedic condition, to formulate a plan of appropriate further diagnostic tests such as radiography, joint taps or computed tomography, and, subsequently, to plan treatment options. Part 1, published in the March issue of *In Practice*, discussed a systematic approach to the orthopaedic examination, from patient presentation to planning and procedure, and considered how this could be applied to the thoracic limb. This article describes how to perform an orthopaedic examination on the pelvic limb. An article published in the February issue of *In Practice* described the use of orthopaedic examination as part of an approach to hindlimb lameness.

Systematic approach

A logical approach is necessary to ensure that all points of an orthopaedic examination are covered and nothing is missed. See Part 1 for a detailed description of the following approach:

- Obtain a full and comprehensive history;
- Perform a general clinical examination;
- Perform an orthopaedic examination to:
  - Observe the dog sitting and standing;
  - Observe the gait;
  - Carry out an orthopaedic physical examination;
- Formulate a list of differential diagnoses and carry out further diagnostic tests as appropriate in order to make a definitive diagnosis.

Order of examination

For a dog presenting with pelvic limb lameness, the author examines the thoracic limbs first, followed by the normal pelvic limb, and finally the abnormal pelvic limb. This avoids being distracted by findings of the affected limb that could otherwise result in omitting or missing findings of the other three limbs.

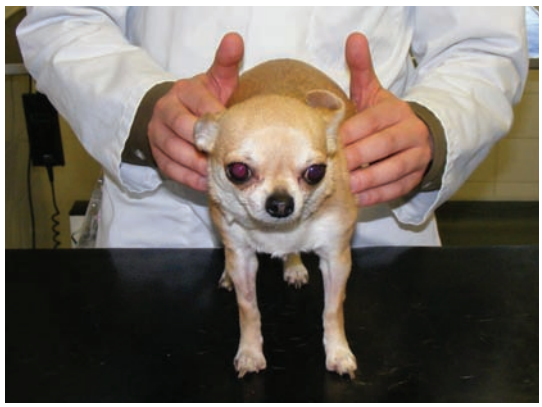

Fig 1: Stand behind the dog and simultaneously palpate the muscles to assess atrophy and symmetry

Examination of the pelvic limb

If possible, start with the dog standing, and stand or crouch behind the dog (Fig 1). Palpate and assess pelvic limb muscle bulk/atrophy with the dog standing. Compare the size of the quadriceps muscle group cranial to the femur and the hamstrings (semitendinosus and semimembranosus muscles) caudal to the femur (Fig 2). These muscles are relatively easy to palpate

Fig 2: Approximate positions of the quadriceps muscle group (red) and hamstring muscles (green) relative to the position of the femur (black)

doi:10.1136/inp.d1813

even in obese dogs. This provides information about which pelvic limb is affected because each affected limb will have muscle atrophy.

Assesses the degree of weightbearing on each limb; ensure the dog is standing evenly and gently push on the plantar aspect of the foot just proximal to the stopper pad with the edge of one or two fingers. The same gentle pressure should be applied to each foot. It takes less pressure to push the foot of the affected limb forwards (due to reduced weightbearing) compared with the normal limbs (Fig 3).

Perform a basic neurological examination. This includes assessing conscious proprioception on all four limbs with the dog standing (eg, knuckling and paper-slide tests) (Jeffrey 2001).

Assess the cervical, thoracic, lumbar and sacral spine to check the full range of movement and pain on deep palpation and manipulation (Fig 4). If these tests results are normal, further neurological examination is generally not indicated. However, if they are abnormal, further neurological assessment is warranted (see Jeffrey 2001).

Fig 3: Use the fingers to push on the plantar aspect of the tarsus to test an animal's resistance to lift the limb. This indicates the degree of weightbearing. If the dog is poorly weightbearing, the tarsus will move easily

Specifically, deep palpation of the lumbosacral joint is necessary to check for pain that may indicate lumbosacral disease (Fig 5).

Perform a tail lift test, whereby the tail is lifted vertically (dorsally) upwards and pushed cranially (Fig 6). A normal dog should tolerate this well. This test is used to assess for lumbosacral disease. A positive pain response is associated with lumbosacral disease but may also suggest a painful tail.

As long as the dog is comfortable, the author performs the remainder of the orthopaedic examination of the pelvic limb in the same position – that is, with the dog standing and facing away. If the dog is uncomfortable standing, or for very large dogs that are almost impossible to examine properly when standing, the rest of the examination should be performed with the dog lying down.

Start distally and work proximally. Examine one pelvic limb at a time but compare left to right sides. If a subtle abnormality is found, comparing left and right sides can help determine whether the finding is significant or not. If bilateral disease is present, comparing left to right sides will ensure that bilateral disease is not missed.

If the patient shows a subtle or unconvincing response to manipulation, repeat the manipulation at least once to check the reliability of the response. If the dog is clearly in pain, such repetition is neither necessary nor indicated.

Fig 4: Palpation of the thoracic and lumbar spine

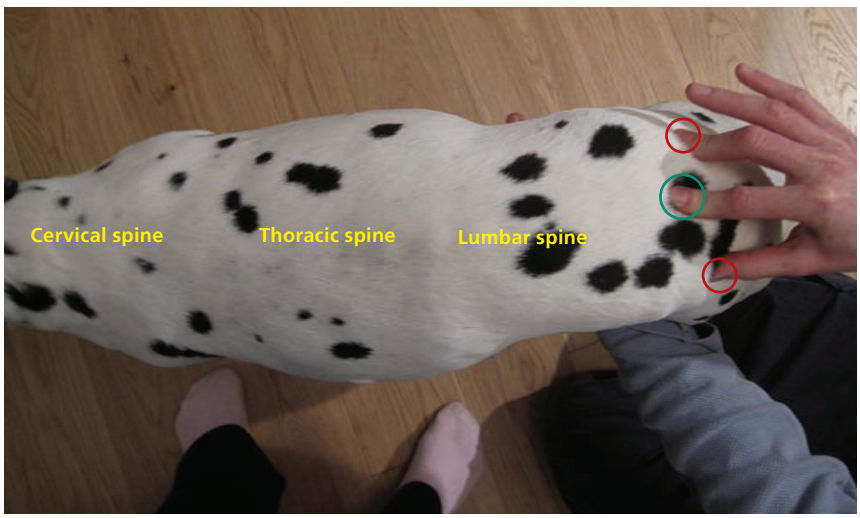

Fig 5: Deep palpation of the lumbosacral spine. Place the thumb and second finger on the left and right ilial crests respectively (red), with the first finger placed between the dorsal spinous processes of the seventh lumbar vertebra and the sacrum (green), and apply ventral (downward) pressure onto the lumbosacral space

Fig 6: The tail lift test is used as a preliminary test for lumbosacral disease and involves elevating the tail and pushing it cranially. A positive pain response is suggestive of lumbosacral disease

Fig 7: Check the claws, pads, interdigital skin and hair carefully for wounds or embedded foreign bodies

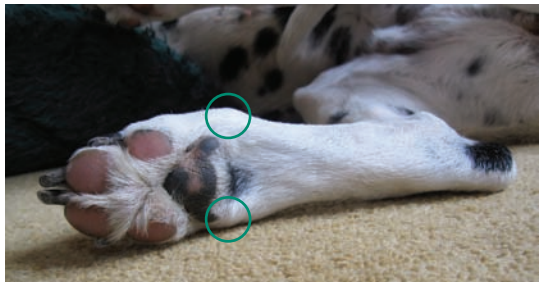

Fig 10: Plantar view of the tarsus in a dog, showing the location of the metatarsophalangeal joints and therefore the plantar sesamoid bones of digits 2 and 5 (green)

Pes (foot)

Examine the digits carefully, methodically and systematically. The digits have a large range of movement in flexion and extension with a reasonable amount of medial and lateral movement. In all cases, check:

- The interdigital skin for signs of dermatitis, wounds or lacerations;
- The interdigital hair for signs of saliva staining;
- The pads (individual digits and large stopper pads) for wounds or embedded foreign bodies (Fig 7);
- The claws and nailbeds for signs of disease or abnormalities;
- Each of the interphalangeal and metatarsophalangeal joints individually for normal, pain-free range of movement in extension and flexion, and for instability medially and laterally (Figs 8, 9). If unsure, compare any suspicious digit to the adjacent digit;
- Each of the proximal and distal interphalangeal joints and the metatarsophalangeal joints individually for swelling, pain, heat or crepitus;
- The metatarsophalangeal joints specifically for pain on deep palpation in the region of the plantar sesamoid bones (particularly sesamoid bones 2 and 7 in affected breeds such as rottweilers) (Fig 10);
- Each of the metatarsal bones individually by moving proximally and palpating to check for swelling, thickening, pain, heat or overlying soft tissue (extensor/flexor tendon) abnormalities.

Hock

The hock works as a constrained hinge joint and has a large range of movement through full extension to flexion. Working distally to proximally, check:

- Hock range of movement. The normal hock should move from about 40° of flexion (Fig 11) to 165° of extension (Fig 12). Full hock extension and flexion is not possible without simultaneous passive stifle

Fig 11 (above): Full hock and stifle flexion. Flexion of the hock cannot be achieved without flexing the stifle concurrently but only the hock should be actively flexed. Fig 12 (left): Hock extension is not possible without simultaneous stifle extension, but only the hock is actively extended

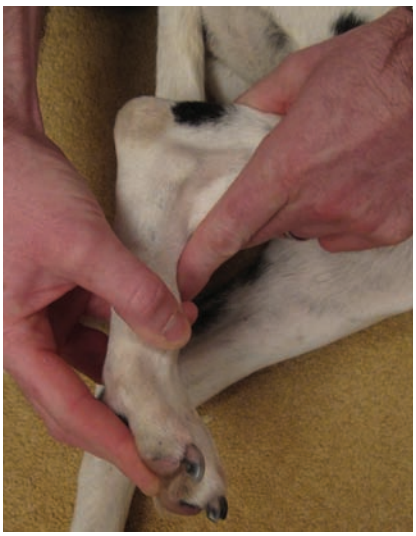

Fig 8: The digits are extended to check range of movement and pain

Fig 9: The digits are flexed to check range of movement and pain

extension and flexion, respectively. The hock joint must be tested actively to test hock range of movement and pain. Certain breeds such as German shepherd dogs have a slightly reduced range of hock movement;

- Medial and lateral hock stability. A normal canine hock has no medial/lateral instability in flexion, but a small amount of laxity may be appreciated in extension;
- Hock swelling/effusion. It is best to palpate this at one of the four pouches of the hock joint that are positioned dorsomedial, dorsolateral, plantaromedial or plantarolateral (Figs 13, 14);
- Pain, crepitus or limited range of movement with any of these manoeuvres.

Invariably, a small firm sesamoid bone can be palpated in the tendon of insertion of the cranial tibial muscle at the point that this tendon crosses from lateral to medial over the dorsal aspect of the hock joint (Fig 14).

Tibia and fibula

Gently palpate the tibia, working from the hock distally to the stifle proximally. Both the lateral and medial malleoli can be palpated distally (Figs 13, 14). Extending proximally, the fibula can only be palpated for a short distance. Almost all the cranial and medial surfaces of the tibia can be palpated from distal to proximal aspects. Landmarks to palpate proximally include the cranial tibial muscle on the proximolateral aspect of the tibia and the tibial tuberosity on the cranial aspect of the proximal tibia. The gastrocnemius muscle can be palpated caudal to the proximal tibia; although the gastrocnemius muscle has medial and lateral bellies, they are not readily distinguishable. The popliteal and digital flexor muscles are situated deep to the gastrocnemius muscle but these cannot be palpated directly. As the gastrocnemius muscle is palpated distally, its size and shape changes as it contributes to and becomes the common calcaneal tendon, which can be palpated right up to the point of insertion on the proximal aspect of the calcaneus (Figs 15, 16). Integrity of the common calcaneal tendon (hock extensor mechanism) can be readily checked – it should not be possible to flex the hock without simultaneous stifle flexion. If the hock is able to flex while the stifle is extended, this indicates common calcaneal tendon mechanism injury. Thickening of the tendon can be an indicator of tendon pathology.

Stifle

The stifle joint is a complex hinge joint. The landmarks of the stifle that should be palpable include the patella, the straight patellar ligament and the tibial tuberosity. These structures form the distal aspect of the quadriceps extensor mechanism on the cranial aspect of the stifle joint. On the lateral aspect of the stifle joint, the fibular head should be palpable on the distal aspect, while the lateral condyle should be palpable just proximal to it; the lateral fabella (the sesamoid of the lateral belly of the gastrocnemius muscle) should be palpable just proximal again (Fig 17).

A small concave depression should be palpable on either side of the patellar ligament, deep to which is the infrapatellar fat pad and stifle joint, which are both not palpable. When a stifle effusion is present, these depressions are either more difficult to appreciate or an effusion is directly palpable. In addition, the lateral and medial borders of the patellar ligament become less distinct to palpate.

In obese dogs, all of these landmarks can be more challenging to palpate due to overlying subcutaneous adipose tissue obscuring them.

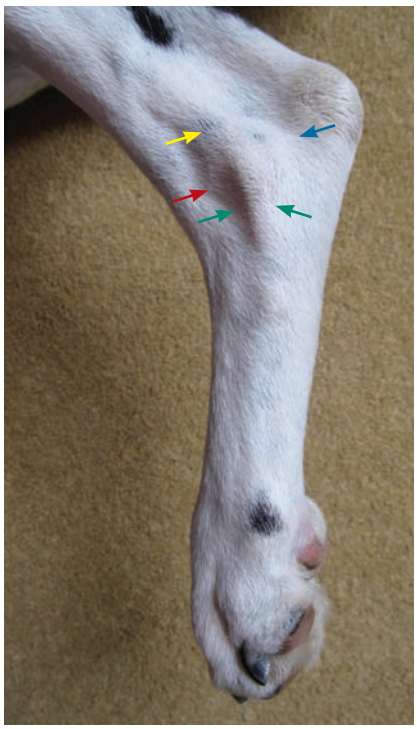

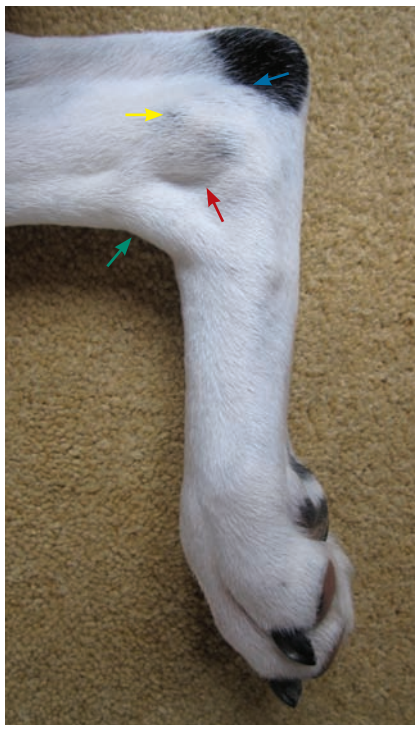

Fig 13 (left): Lateral aspect of the tarsus showing the lateral malleolus/distal fibula (yellow arrow), the lateral collateral ligament (green arrows), and the dorsolateral (red arrow) and plantarolateral (blue arrow) palpation points for synovial effusion. Fig 14 (right): Medial aspect of the tarsus showing the medial malleolus of the tibia (yellow arrow), the tendon of the cranial tibial muscle (green arrow), and the dorsomedial (red arrow) and plantaromedial (blue arrow) palpation points for synovial effusion



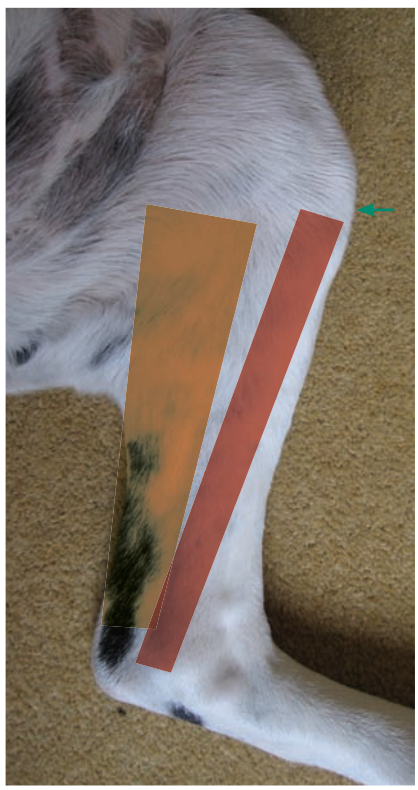

Fig 15: Lateral aspect of the tibia showing approximate positions of the palpable distal fibula (red), the tibial tuberosity (green arrow), the cranial tibial muscle (yellow) and the common calcaneal mechanism (orange). Fig 16: Medial aspect of the tibia showing approximate positions of the palpable tibia (red), the tibial tuberosity (green arrow) and the common calcaneal mechanism (orange)

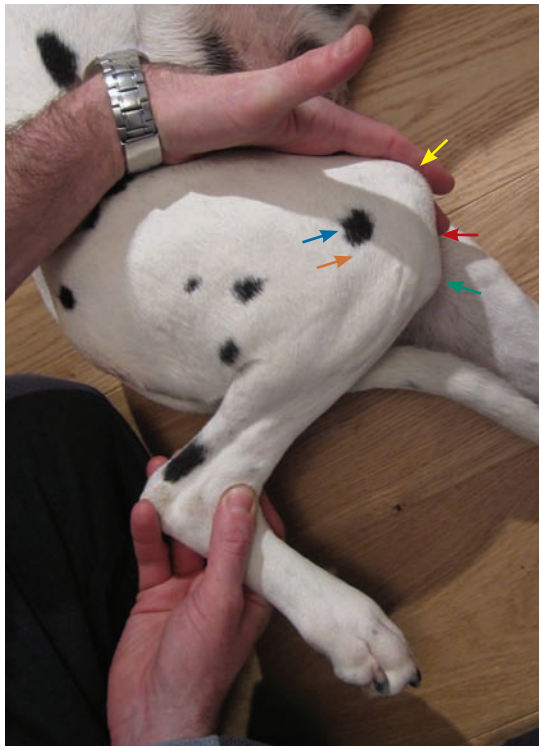

Fig 17: Palpation points of the stifle. Patella (yellow arrow), patellar ligament (red arrow), tibial tuberosity (green arrow), lateral fabella (blue arrow) and the fibular head (orange arrow)

The stifle's full range of movement should be from flexion of 40° where the crus (tibia and associated soft tissues) touch the hamstrings (Fig 11) through to extension of about 160° (Fig 18). Full range of movement should be possible without pain or instability. As the stifle is extended, the hock will extend secondarily. Check lateral and medial collateral ligament stability and integrity – there should be no instability.

The patella should track normally in the trochlear groove through a full range of extension and flexion. Patellar luxation is most easy to appreciate starting with the stifle in full extension and then gradually flexing the stifle. If the patella luxates as the stifle is flexed, the patella will typically stay luxated until the stifle is extended again. If the patella seems stable through a normal range of stifle movement, it should be tested further by placing gentle lateral and then medial pressure on the patella while the stifle is flexed. Patellar stability can subsequently be tested by internally and then externally rotating the tibia while the stifle is flexed; not all dogs will tolerate this while conscious.

Craniocaudal stability of the stifle should be tested. This is usually used to check the integrity of the cranial cruciate ligament but caudal cruciate ligament instability can occur in rare cases. There are two ways of testing craniocaudal stability of the stifle:

- Cranial drawer test (Fig 19);
- Tibial thrust test (Fig 20).

Although both of these can be performed in the conscious dog, they are more reliably performed with the animal sedated or anaesthetised, and placed in lateral recumbency.

Fig 18: Full stifle extension. The distal femur, quadriceps and patella should be supported by one hand and the stifle extended by advancing the distal tibia and hock cranially with the other hand. The hock should be supported in the second hand and, although hock extension is unavoidable, the hock should not be actively extended

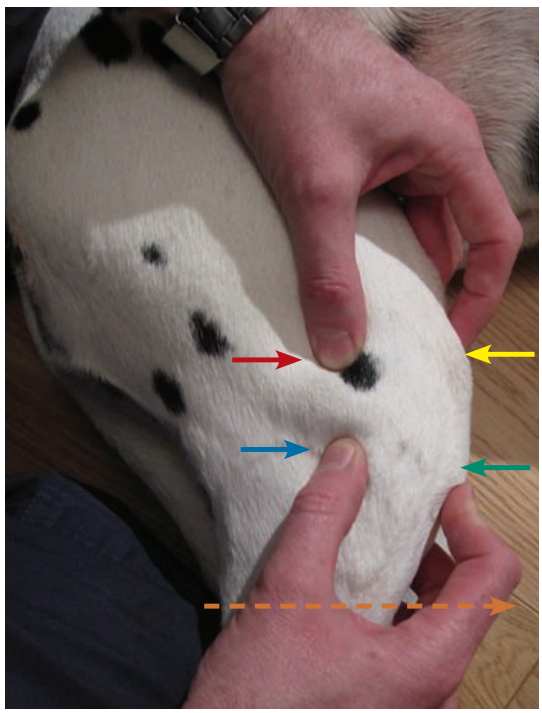

Fig 19: Stifle showing the palpation reference points for the cranial drawer test, which are the lateral fabella (red arrow), the patella (yellow arrow), the tibial tuberosity (green arrow) and the fibular head (blue arrow). The hand grasping the tibia should attempt to move cranially relative to the femur (in the direction of the dashed orange arrow). A positive cranial drawer test is indicated if the tibia moves cranially

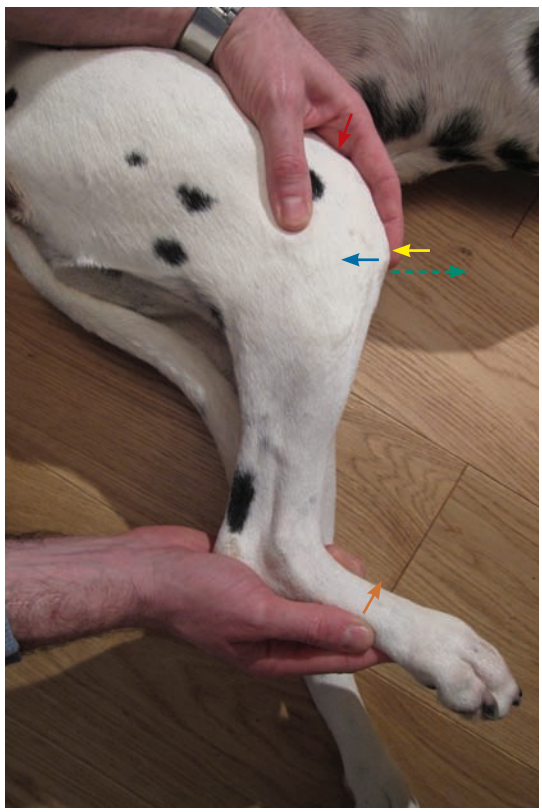

Fig 20: Stifle showing the palpation points for the tibial thrust test. The stifle should be cupped in one hand, with the patella (red arrow) approximately under the palm of the hand. The index finger should extend down over the patellar ligament to rest on the tibial tuberosity (yellow arrow) – this finger should be used to apply caudal pressure on the tibial tuberosity (blue arrow). The other hand should be used to support the foot with the fingers extending distally. This hand should apply firm force to the plantar aspect of the tarsus causing slight hock flexion and simulating the force of weightbearing (orange arrow). A positive cranial tibial thrust test is indicated if the tibial tuberosity displaces cranially (dashed green arrow). This test is repeated at different angles of stifle extension/flexion

Cranial drawer test

The cranial drawer test involves grasping the stifle in two hands (Fig 19). For the right stifle, the dog should be placed in left lateral recumbency and the clinician positioned behind the dog. The proximal tibia should be taken in the right hand with the thumb on the fibular head and the index finger on the tibial tuberosity. The distal femur should be taken in the left hand with the thumb over the lateral fabella and the index finger on the patella. (These positions are reversed for the left stifle.) It is very important that the fingers and thumbs are placed on the bony landmarks and not on the adjacent soft tissues. The stifle should be grasped firmly but gently, and the hand on the tibia should be positioned caudally in case the tibia is already subluxated. The proximal tibia should then be pushed cranially relative to the distal femur. The stifle should be stable and movement should not be possible. A dog that has cranial cruciate ligament instability will show cranial movement of the proximal tibia relative to the distal femur, and the end point is frequently indistinct. Performing this test successfully requires practice to develop the correct technique (this is a test of technique and not operator strength!). False positive results can occur in:

- Young puppies, which have relatively lax stifles and may have apparent craniocaudal instability. This can be distinguished from pathological cruciate instability as there is no associated stifle effusion and the craniocaudal 'instability' will have a well defined end point. In addition, the 'instability' should be identical between left and right stifles;
- Some adult dogs that have mild cranial 'instability' of the tibia relative to the femur in association with mild internal rotational 'instability' of the tibia – this is normal. This can be distinguished from pathological cruciate instability as there is no associated stifle effusion, the 'instability' has a clearly defined end point, and there is no difference between the suspected and the contralateral stifle. In addition, if the test is repeated and internal rotation of the tibia is prevented by the hand on the tibia, craniocaudal 'instability' will also be controlled and eliminated.

A false negative result for cranial drawer cruciate instability can occur when there is a partial cranial cruciate ligament rupture or when the degree of stifle effusion or periarticular thickening/fibrosis is such that this contributes to stifle stability and therefore masks craniocaudal stifle instability.

Tibial thrust test

For the right stifle, the tibial thrust test involves placing the dog in left lateral recumbency (Fig 20). The stifle should be cupped by the palm of the left hand and the index finger extended distally so that the tip of the finger exerts gentle caudal pressure on the tibial tuberosity. The foot should be taken in the right hand with the calcaneus cupped by the palm and the fingers extended distally towards the digits. Start with the stifle fully flexed and then work incrementally through to full extension. At each incremental angle of stifle extension, firm pressure should be applied to the plantar aspect of the tarsus using the fingers of the right hand

– this mimics the force of weightbearing through the limb and causes slight hock flexion. Displacement of the tibial tuberosity is monitored by observing it and by using the third finger of the left hand to feel it. If the tibial tuberosity moves cranial relative to the femur, this is a positive cranial tibial thrust test. This can occur at different angles of stifle flexion/extension, so the test should be repeated throughout the full range of stifle movement. A positive cranial tibial thrust test indicates cranial cruciate ligament disease/rupture.

Femur

The condyle of the distal femur and the greater trochanter of the proximal femur are easily palpated in all but the most obese patients. The majority of the femoral diaphysis in between is not palpable due to overlying muscles that can be palpated separately; these include the quadriceps group cranial to the femur, tensor fascia lata and biceps femoris muscles lateral and caudal to the femur, semimembranosus and semitendinosus muscles caudal to the femur, and adductor, gracilis and pectineus muscles medial to the femur. Abnormalities of these muscle groups are unusual, with the most common palpable abnormality being muscle atrophy, which reflects chronic pelvic limb lameness. There is usually a palpable reduction in the size of the quadriceps and hamstring muscle groups (Fig 2).

Hip

The hip is a ball and socket joint comprising the acetabulum and femoral head. This allows the joint to move in three dimensions: extension/flexion, internal/external rotation and abduction/adduction. A normal hip has a wide range of pain- and crepitus-free movement; the hip should flex to about 50° (Fig 21) and extend to about 160° (Fig 22).

It is impossible to fully extend the hip without simultaneously extending the stifle and increasing patellofemoral contact pressure. If concurrent stifle pathology exists, this may cause stifle pain, which will give a false positive pain response to hip extension. A positive pain response to hip extension must therefore be interpreted carefully and stifle pathology ruled out to avoid a false positive result. If independent stifle

Fig 21: Full hip flexion involves supporting the pelvis with one hand while the other flexes the hip, bringing the stifle up to contact the body

Fig 22: Full hip extension involves supporting the pelvis with one hand while the stifle is cupped in the palm of the other hand and the hip is extended



Fig 23: Anatomic landmarks of the pelvis are the dorsal ilial spine (yellow), the ischial tuberosity (red) and the greater trochanter of the femur (orange). Relative positions map an inverted triangle (green dashed lines) in the normal pelvis but this relationship is lost in, for example, cases of craniodorsal hip luxation when the greater trochanter displaces dorsally (blue arrow)

extension shows no pain response, this makes such a false positive result for hip pain less likely. A false positive pain response to hip extension can also occur if lumbosacral pathology exists because extending the hip also exerts pressure onto the lumbosacral spine. Lumbosacral pain should therefore be separately investigated by careful examination of the area as previously described.

Barden hip lift and Ortolani tests assess hip laxity (Witte and Scott 2011, Houlton 1994, Piermattei and others 2006), and are usually employed in skeletally immature dogs. They are an important part of the orthopaedic work-up of a dog with hip dysplasia, but usually not part of the initial assessment. These are potentially painful tests for the dog and should only be performed under sedation or general anaesthesia.

Pelvis

The pelvis should be palpated for symmetry and stability, and the dog should be checked to make sure it does not experience pain on palpation. Anatomic landmarks to palpate include the ischial tuberosity, the greater trochanter of the femur, and the cranial dorsal ilial spine. Each of these structures should be palpated to check for discomfort, swelling, and any change in texture, shape or position. The relative positions of these three landmarks make the shape of an inverted triangle in the normal patient (Fig 23). This relationship is lost in instances of pelvic fractures or hip luxations. For example, if a dog suffers a craniodorsal hip luxation, the greater trochanter moves dorsally and typically lies immediately in between the ischial tuberosity and the dorsal ilial spine (ie, the inverted triangle shape is lost).

Further reading

ARTHURS, G. (2011) Orthopaedic examination of the dog 1. Thoracic limb. *In Practice* **33**, 126-133

HOULTON, J. E. F. (1994) A problem orientated approach to the diagnosis of joint disease. In BSAVA Manual of Small Animal Arthrology. Eds J. E. F. Houlton & R. W. Collinson. BSAVA Publications. pp 8-21

JAEGGER, G., MARCELLIN-LITTLE, D. J. & LEVINE, D. (2002) Reliability of goniometry in Labrador retrievers. *American Journal of Veterinary Research* **63**, 979-986

JEFFERY, N. (2001) Neurological examination of dogs 1. Techniques. *In Practice* **23**, 118-130

PIERMATTEI, D. L., FLO, G. L. & DECAMP, C. E. (Eds) (2006) Orthopedic examination and diagnostic tools. In Handbook of Small Animal Orthopaedics and Fracture Repair, 4th edn. Saunders Elsevier. pp 3-24

WITTE, P. & SCOTT, H. (2011) Investigation of lameness in dogs 2. Hindlimb. *In Practice* **33**, 58-66

In Practice

Orthopaedic examination of the dog : 2. Pelvic limb

Gareth Arthurs

In Practice 2011 33: 172-179
doi: 10.1136/inp.d1813