Causes of otitis externa in the dog

Jane Coatesworth MA VetMB CertVD MRCVS
ANIMAL HEALTH TRUST, LANWADES PARK, KENTFORD, NEWMARKET, SUFFOLK. CB8 7UU

ABSTRACT: Otitis externa can involve a number of interlinked factors. These factors may directly induce inflammation, may increase the likelihood of inflammation occurring, or may maintain inflammation even when the primary factor has resolved. This article discusses how the recognition of specific primary, predisposing and perpetuating factors can greatly assist us in successfully unravelling and treating an individual case. *DOI: 10.1111/j.2044-3862.2011.00085.x*

Inflammation of the ear canal, otitis externa, is a common clinical finding in the dog. It may be limited to inflammation of the modified skin lining of the external ear canal or may be part of a wider pathology of the middle ear or ear pinna. The ear canal can be thought of as a tubular extension of the skin ending at the ear drum. In reality, local epithelial-cell production starts at the tympanic membrane and moves outwards, forming part of the self-cleansing mechanism of the ear.

A case of otitis externa often encompasses a number of interlinked factors. 'The Three Ps' can help us to remember this diversity and diagnose and treat cases appropriately:

1. **Primary** factors – directly induce inflammation in the ear canal
2. **Predisposing** factors – increase the likelihood of an ear developing inflammation
3. **Perpetuating** factors – develop as a consequence of inflammation and maintain inflammation even though the primary factors may have resolved

A fourth P (**Prompt** treatment) reminds us that chronic inflammation leads to remodelling of the external ear, and eventual irreversible change. Prompt treatment avoids these unhelpful sequelae, and allows easier assessment of the multiple factors present.

PRIMARY FACTORS

- trauma
- hypersensitivity
- parasites
- foreign bodies
- keratinisation disorders
- autoimmune disease
- hypothyroidism
- juvenile cellulitis.

Trauma

The external ear has a thin, delicate lining of epithelial cells that are readily abraded and damaged by overzealous cleaning and hair plucking. Cotton buds are useful for taking cytology samples and absorbing exudates but can cause considerable trauma when rubbed up and down the ear lining. The simultaneous plucking of large amounts of hair from the ear canal can cause traumatic inflammation of the epithelium. Hairy-eared individuals, with a history of otitis externa, will benefit from a little-and-often approach to hair plucking. The value of prophylactic hair plucking in hairy-eared dogs without a history of otitis externa is uncertain.

Hypersensitivity

Hypersensitivity conditions include atopic dermatitis, cutaneous adverse food reactions and contact reactions.

Atopic dermatitis

Atopic dermatitis occurs when individuals have an inflammatory and pruritic skin response to specific environmental allergens (Fig. 1). It is associated with a range of characteristic clinical signs, including recurrent otitis externa. The otitis may be seasonal or non-seasonal depending on which allergens are relevant for the individual dog. Otitis is typically mild and uncomplicated in the early stages, becoming more severe if treatment is delayed or inadequate.

Cutaneous adverse food reaction

Cutaneous adverse food reaction should be considered in all cases of chronic otitis, even unilateral ones. The term encompasses reactions to food caused by immunological (food allergy) and non-immunological (food intolerance) mechanisms. The mechanism in dogs is rarely identified. Pruritus

CPD

Fig. 1: *Atopic German Shepherd with erythema and hypotrichosis of the face and pinna.*

often involves the face, ears, perineum, distal limbs and ventrum. Secondary skin and ear infections with bacteria and *Malassezia* are common. Up to 20% of cases have concurrent gastrointestinal signs. The condition cannot be distinguished from non-seasonal atopy on clinical signs, although it is, in contrast to atopy, poorly responsive to glucocorticoids and may be seen at an earlier age. Dogs have normally been fed the problematic diet for some time rather than it being due to a recent change. Approximately one-third of children with atopic dermatitis have concurrent food allergy. Concurrent hypersensitivities should also be looked for in dogs.

Contact reactions

Contact reactions to ear cleaners and medicated ear drops have been reported. Individuals may react to components such as propylene glycol, alcohol or neomycin. This could also be considered to be a perpetuating factor.

Parasites

Mites

Otodectes cyanotis is the most common otic parasite, especially in young puppies in a communal situation. *Otodectes* is a non-burrowing psoroptic mite, which has chewing mouthparts. Inflammation is thought to arise from a combination of physical damage and a hypersensitivity response to mite allergen. *Otodectes* has a three-week lifecycle, allowing mite numbers to increase rapidly. *Demodex canis*, *Sarcoptes* and *Trombicula* can be found on cytology from exudate in the external ear, but the author has not seen these in the absence of wider skin lesions associated with them.

Ticks

Various tick species may occasionally attach in the external ear causing local pain and inflammation. The spinose ear tick, *Otobius megnini,* may be seen in imported dogs. It is resident in North and South America, India and Southern Africa. The larvae and nymphs attach for several months deep in the external ear and feed, eliciting a waxy exudate and severe inflammation.

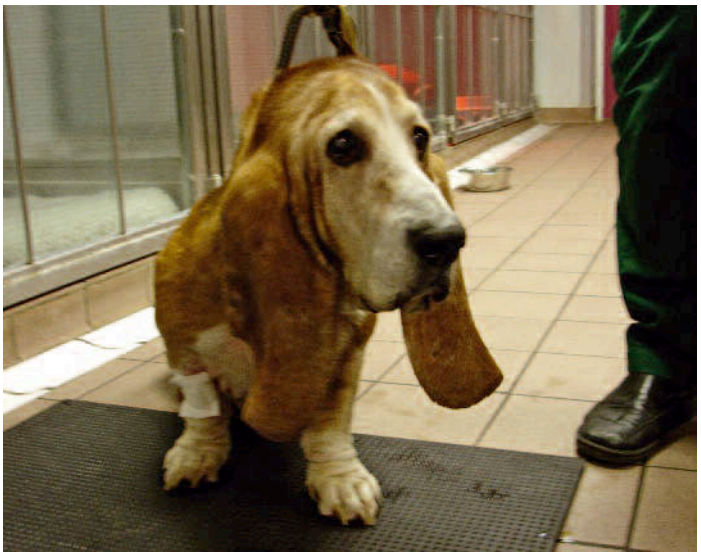

Fig. 2: *Bassett Hound with heavy, pendulous pinnae.*

Foreign bodies

Acute unilateral otitis externa is often associated with a grass-awn foreign body. This dry spiky plant material causes physical irritation. The arrowhead shape migrates in one direction only and may rupture the tympanic membrane. Sand and soil can accumulate when dogs dig, roll or frequent wind-blown beaches. Dried medication may also act as a foreign body, although this may be classed as a perpetuating factor.

Keratinisation disorders

Keratinisation disorders, e.g. idiopathic seborrhoea of the American Cocker Spaniel, lead to changes in the secretions from the ceruminous and sebaceous glands of the ear canal, and increased epithelial turnover time. The combination produces keratosebaceous debris in the external ear and an altered environment that favours microbial growth.

Autoimmune skin disease

The autoimmune skin diseases pemphigus foliaceus, pemphigus vulgaris and systemic lupus erythematosus may cause lesions extending down the external ear canal and causing otitis externa. Pemphigus foliaceus, the most common autoimmune skin disease in the dog, causes breakdown of cell-to-cell adhesion in the stratum corneum and subsequent pustules, crusts, erosions and excess scale.

Hypothyroidism

Hypothyroidism is the most common canine endocrinopathy. Low thyroid hormone levels have profound effects on the skin, including altered fatty acid profiles of ceruminal lipids, increased sebaceous gland activity and reduced immune capacity. These changes may result in a seborrhoeic otitis with secondary infection.

Juvenile cellulitis

Juvenile cellulitis affects puppies from three weeks to four months of age. The skin lesions of papules, sterile pustules, ulcers and exudation may, as well as affecting the muzzle, eyelids and lips, also involve the lining epithelium of the ear.

PREDISPOSING FACTORS

- conformation
- maceration
- obstruction - polyps, neoplasia
- systemic immunosuppression
- raised environmental temperature and humidity.

Predisposing factors change the environment of the external ear, often affecting the local temperature and humidity and preventing good ventilation. Dog breeding has produced a wide diversity of ear conformation. Unhelpful conformational features include the hairy ear canal of the Poodle, the hairy

concave pinna of the Spaniel, the rigid occlusive pinna and stenotic ear canal of the Shar Pei and the heavy pendulous pinnas of the Bloodhound and Bassett (Fig. 2).

Repeated wetting of the ear canals, e.g. when an owner cleans with water or a dog swims regularly, can cause maceration of the epithelium and consequent reduction of skin-barrier function. Physical obstruction of the ear canal by neoplasia, a nasopharyngeal polyp or dried medication can change the local microclimate.

Dogs with hyperadrenocorticism, or dogs receiving immunosuppressive medication, will be predisposed to opportunistic infections, including in the ears, and high ambient external temperature and humidity may affect the resident bacterial and yeast population of ears.

Fig. 3: *Epithelial ulceration and copious exudate in a Bassett Hound with* Pseudomonas *otitis externa.*

PERPETUATING FACTORS

- bacteria
- yeasts
- otitis media
- chronic inflammation.

When primary factors are not addressed, or symptomatic treatment is inadequate, pathological changes can progress in severity, and pathogenic organisms can become established. Early bacterial infections often involve Gram +ve *Staphylococcus* spp. and *Streptococcus* spp. while chronic infections involve the Gram -ve rods *Proteus* spp., *Klebsiella* spp., *E. coli* and/or *Pseudomonas* spp. *Pseudomonas* is an opportunistic invader, particularly in wet ears, where the resident commensal population is absent, perhaps after repeated antibiotic therapy. The release of lytic enzymes by *Pseudomonas* causes ulceration of the lining epithelium, severe inflammation and pain (Fig. 3).

The yeast *Malassezia* can be a commensal of normal ears. Overpopulation and infection occur when the

Fig. 4: *Chronic inflammatory change and* Malassezia *overgrowth perpetuating otitis in a Cairn Terrier.*

local microclimate is altered in its favour, particularly with the removal of competing bacteria by antibiotic therapy, alterations in lipid composition in the cerumen and changes of temperature and humidity (Fig. 4). *Candida* infection in the external ear is uncommon in the UK but has been reported in warmer climates.

Otitis media is usually a product of extension from otitis externa through a ruptured tympanic membrane. It has been estimated that approximately 16% of acute otitis externa cases and 50% of chronic ones have a concurrent otitis media. Primary otitis media, in which the tympanic membrane is intact and infection extends through the Eustachian tube from the nasopharynx, is rare in the dog.

Chronic inflammatory change can significantly alter the ear architecture (Fig. 4). The epithelial lining responds to repeated insult with thickening, hyperplasia of the ceruminous glands, reduced epithelial cell migration and associated self-cleaning, narrowing of the free space and increased humidity in the ear-canal lumen. With time the ear cartilage may become calcified and the free space closed irreversibly.

SUMMARY

In summary, otitis externa can involve a number of interlinked factors. These factors may directly induce inflammation, may increase the likelihood of inflammation occurring, or may maintain inflammation even when the primary factor has resolved. Recognition of specific primary, predisposing and perpetuating factors can greatly assist us in successfully unravelling and treating an individual case.

CPD CONTINUING PROFESSIONAL DEVELOPMENT SPONSORED BY BAYER ANIMAL HEALTH

These multiple choice questions are based on the above text. Answers appear on page 47 of the print version, and as supporting information in the online version of this article.

1. The Three Ps are:

a. primary factors
b. problematic factors
c. predisposing factors
d. perplexing factors
e. perpetuating factors

2. *Otodectes cyanotis*:

a. has a 2-week life cycle
b. has a 3-week life cycle
c. is a non-burrowing mite
d. is a burrowing mite
e. is the most common otic parasite

3. Atopic dermatitis is a common underlying cause of recurrent otitis externa:

a. true
b. false

4. Repeated wetting of the ear canal can predispose to otitis externa:

a. true
b. false

5. Bacteria and yeasts:

a. are primary factors in otitis externa
b. predispose a patient to otitis externa
c. can perpetuate cases of otitis externa